

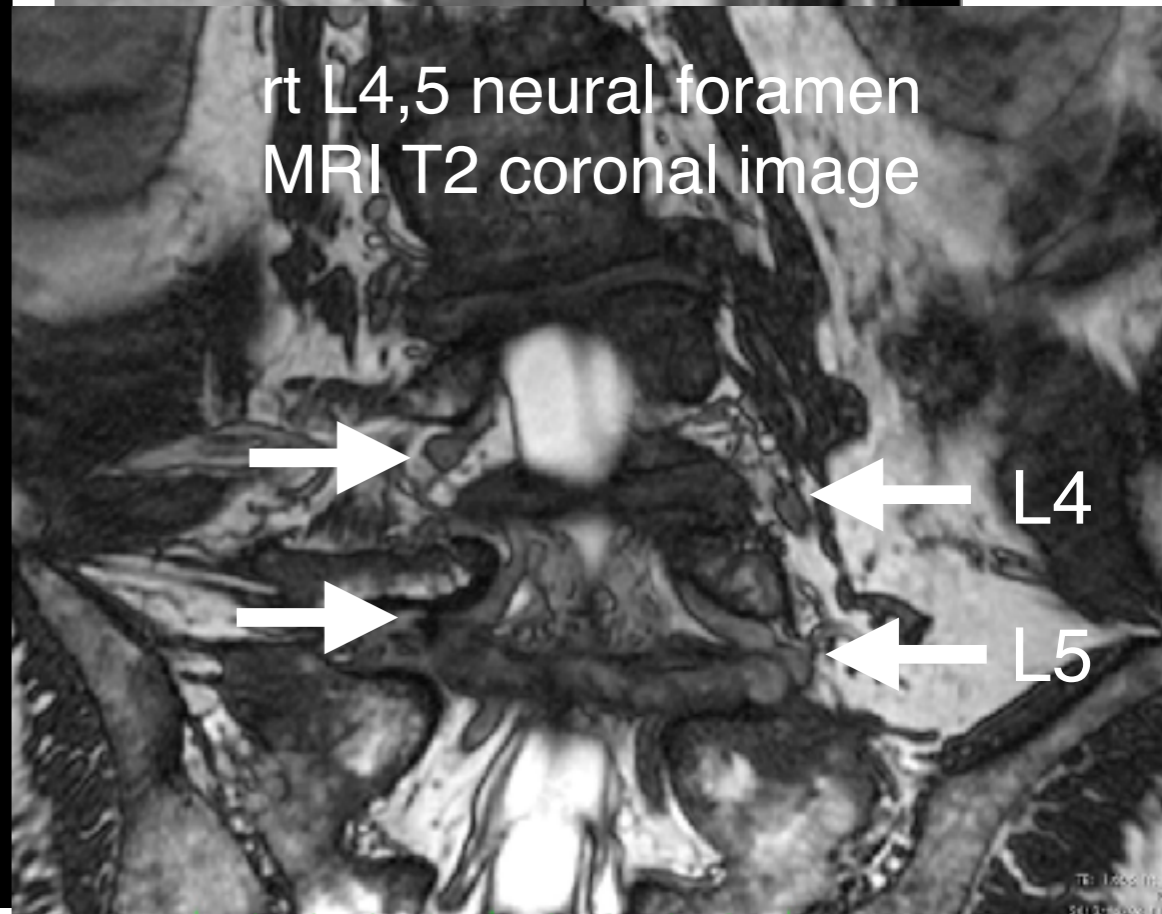
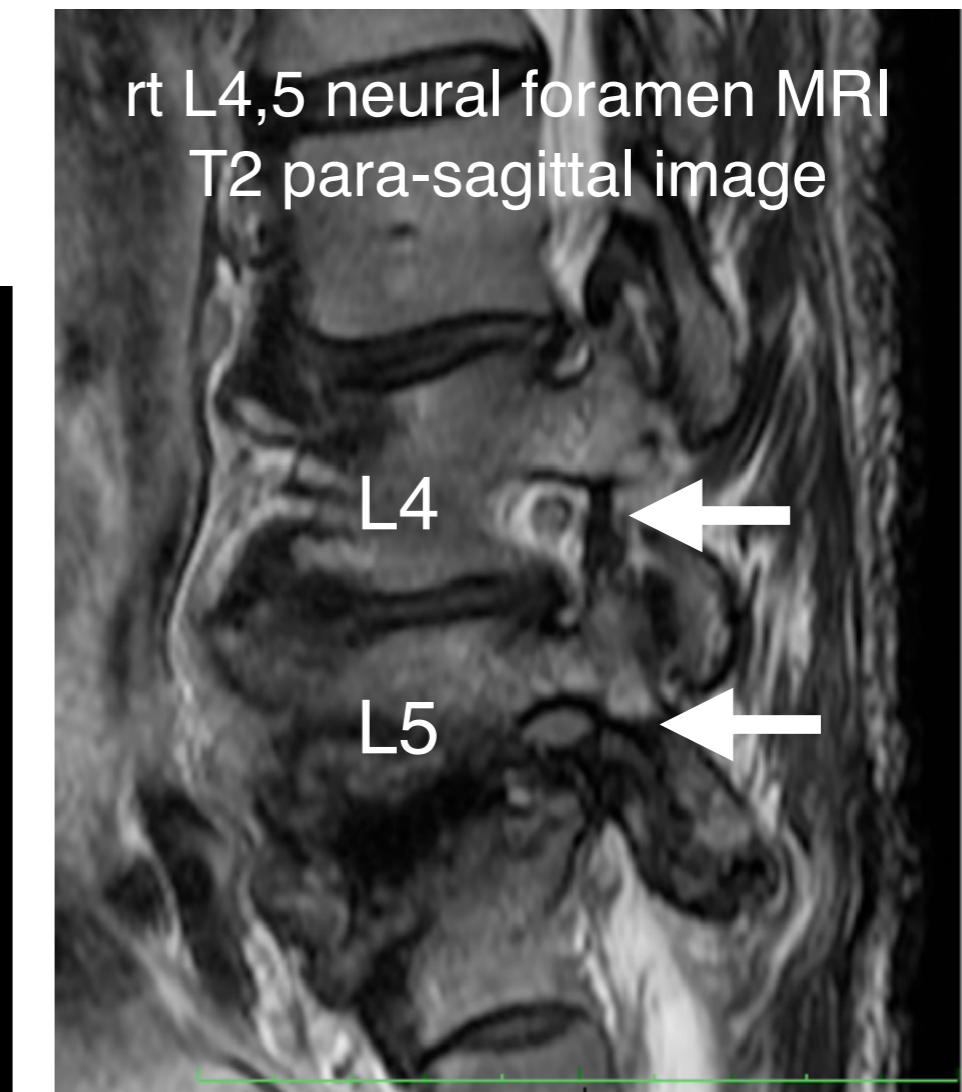
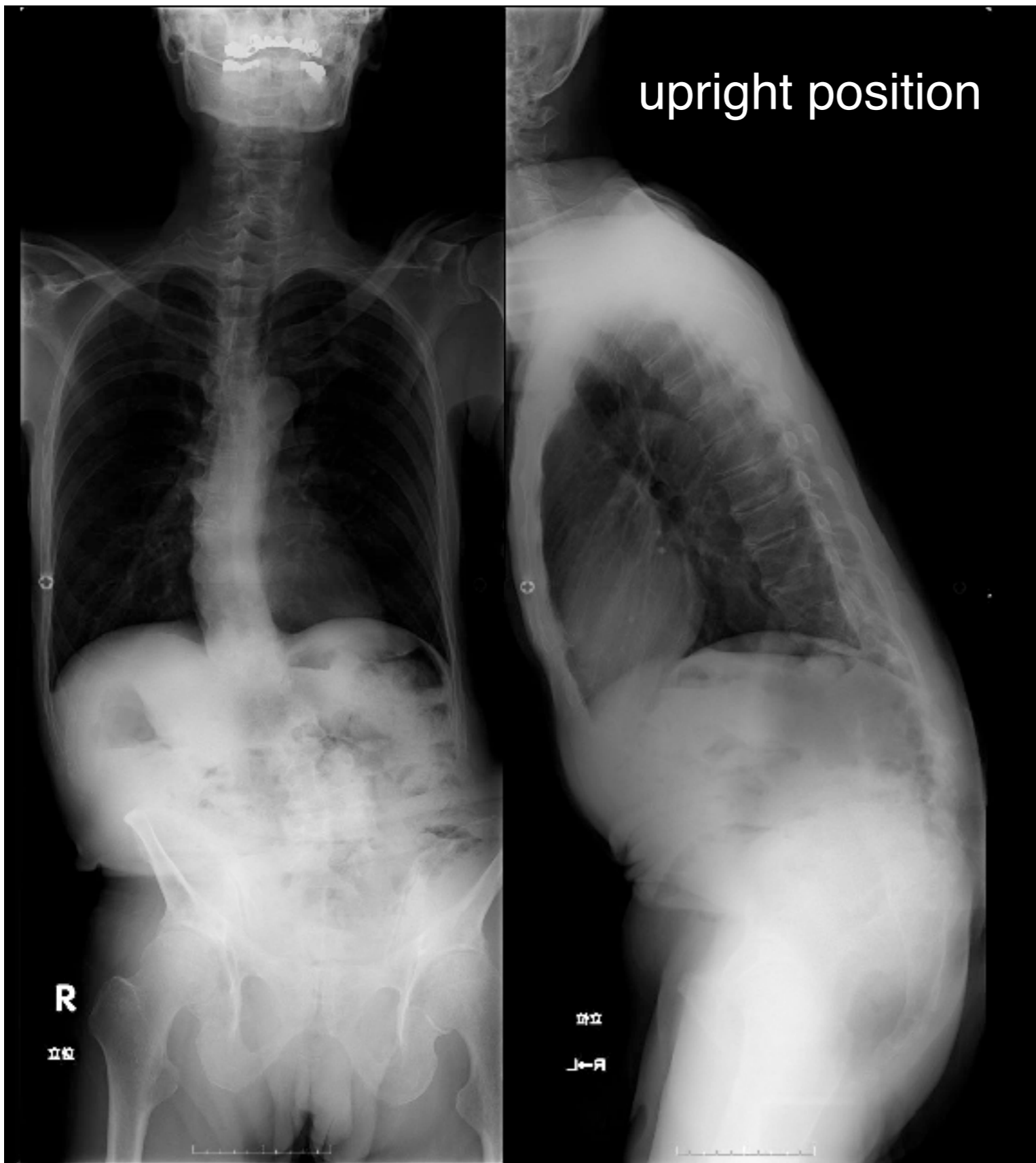
主題 困難な症例への挑戦の演題応募の仕方

- 演題募集ページより 主題2を選択
- 演題名の冒頭に応募したい症例 (case 1-4) を示し、あなたの治療戦略を象徴するタイトルを付けて下さい
- 例：和文: case 3: 薬物療法による除痛と経過観察
英文 case 3: close MRI follow up under medical pain control
- 演題本文には治療戦略の概要と、他の考えられる治療選択肢の中からあえてそれを選ぶ根拠を記入して下さい
- 採否は会長に御一任ください。 主題として全てが採用しきれない場合は、一般演題に主題関連として採用となる可能性があります

case 1

- 63 yo male
- patient with Parkinson disease since last 10 years under medication
- slowly progressive scoliosis in the last few years
- prominent continuous leg pain at Rt L5 area in the last few months

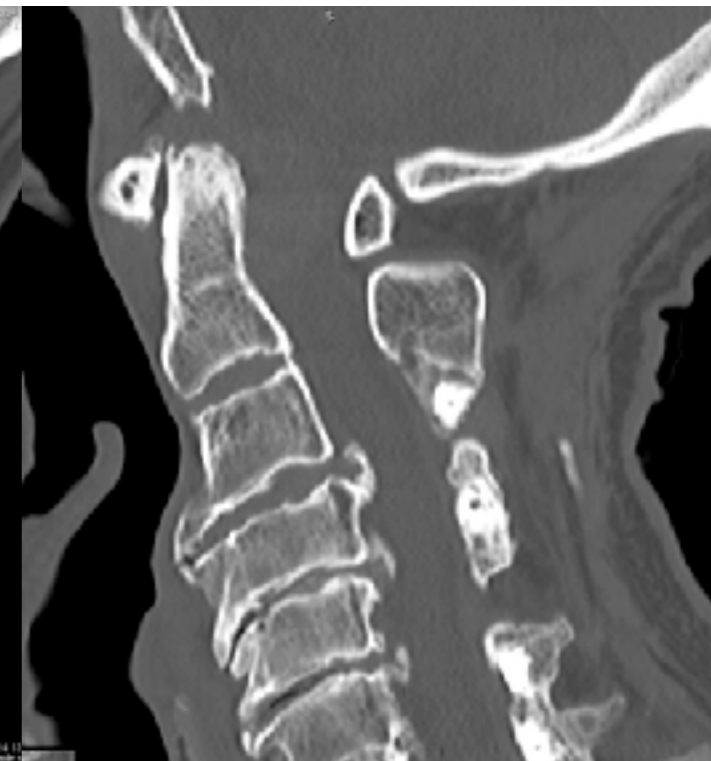
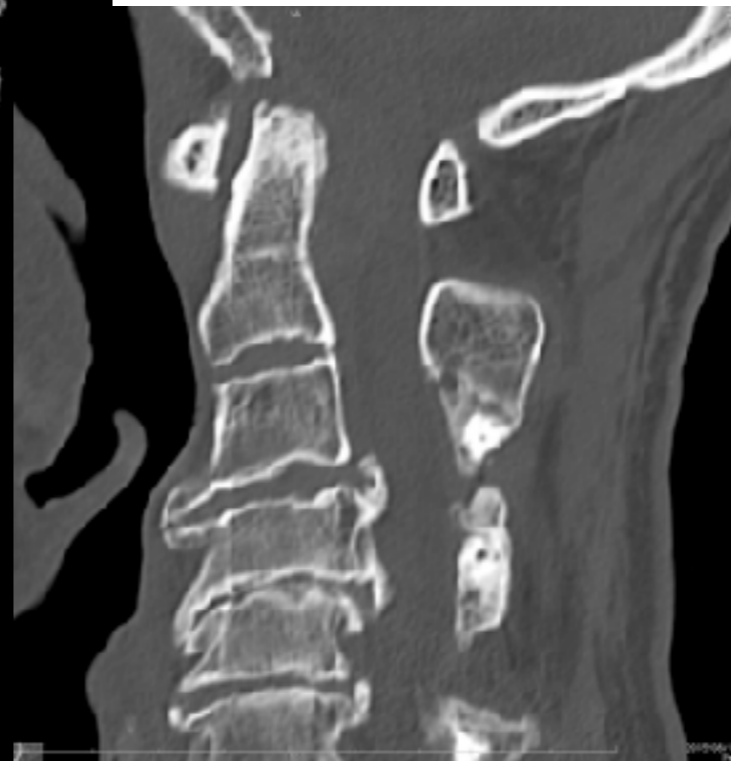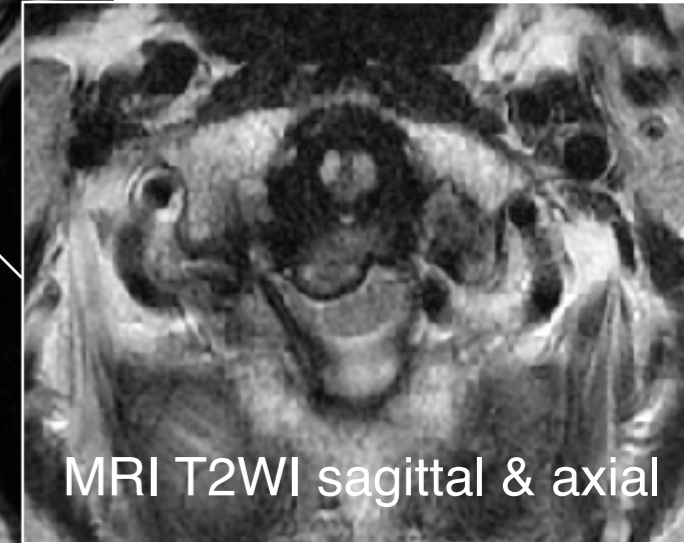
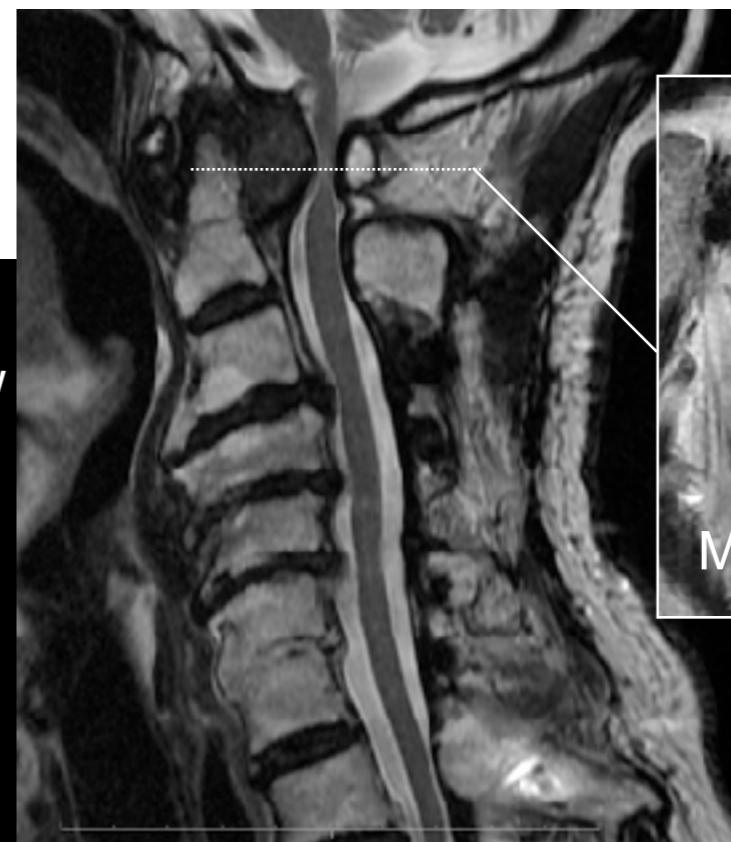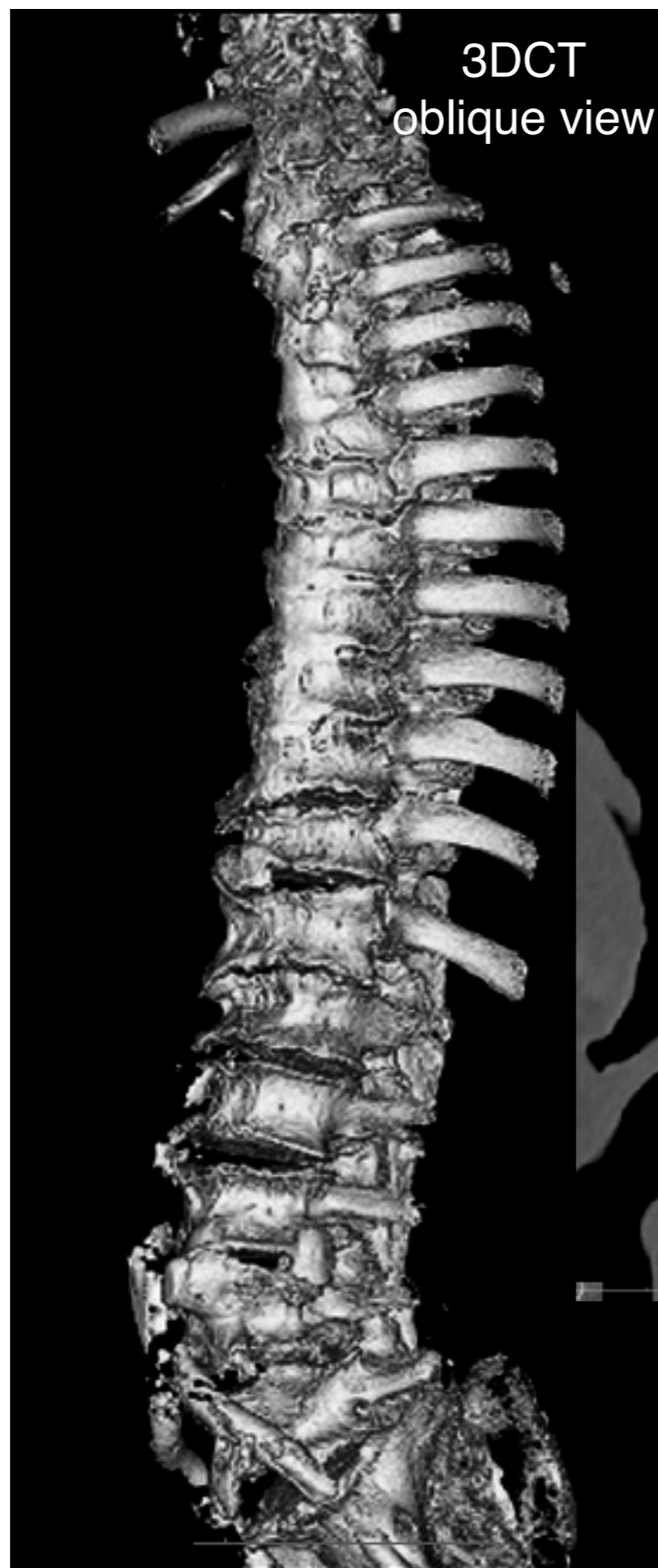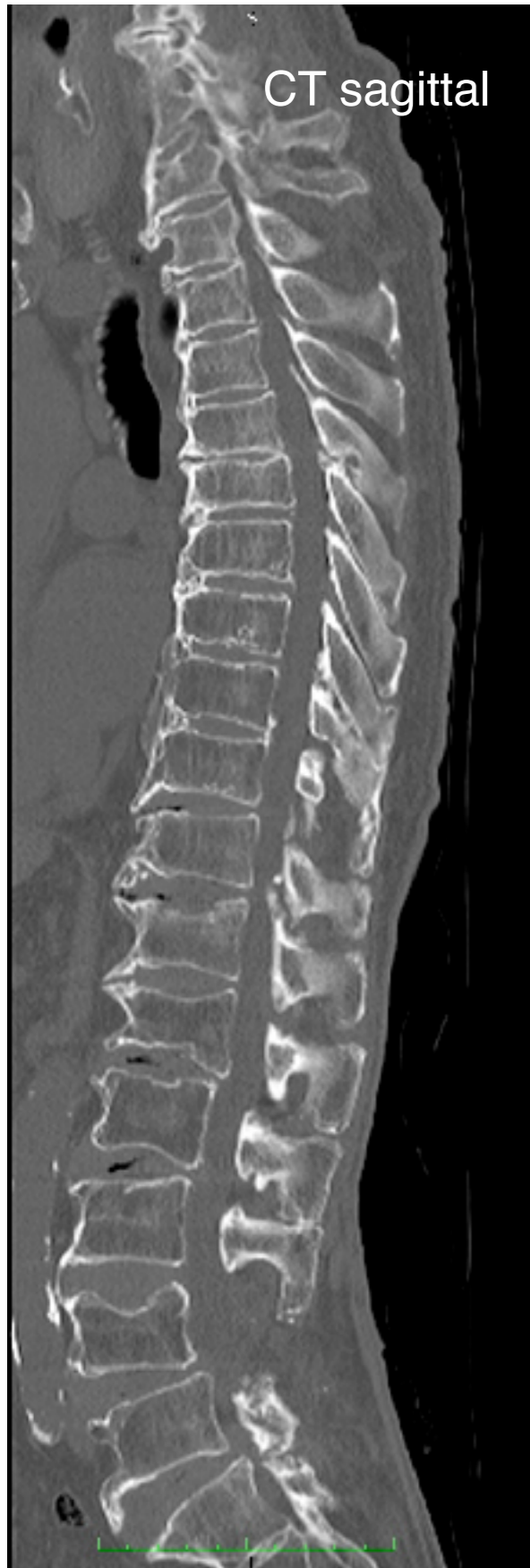case 1



case 2

- 84 yo male, DISH patient
- OPLL cervical laminoplasty at 64 yo
- multiple lumbar and thoracic partial laminectomy in the last 15 years
- temporal tetraparesis after minor head injury 2 weeks ago with almost complete recovery

case 2

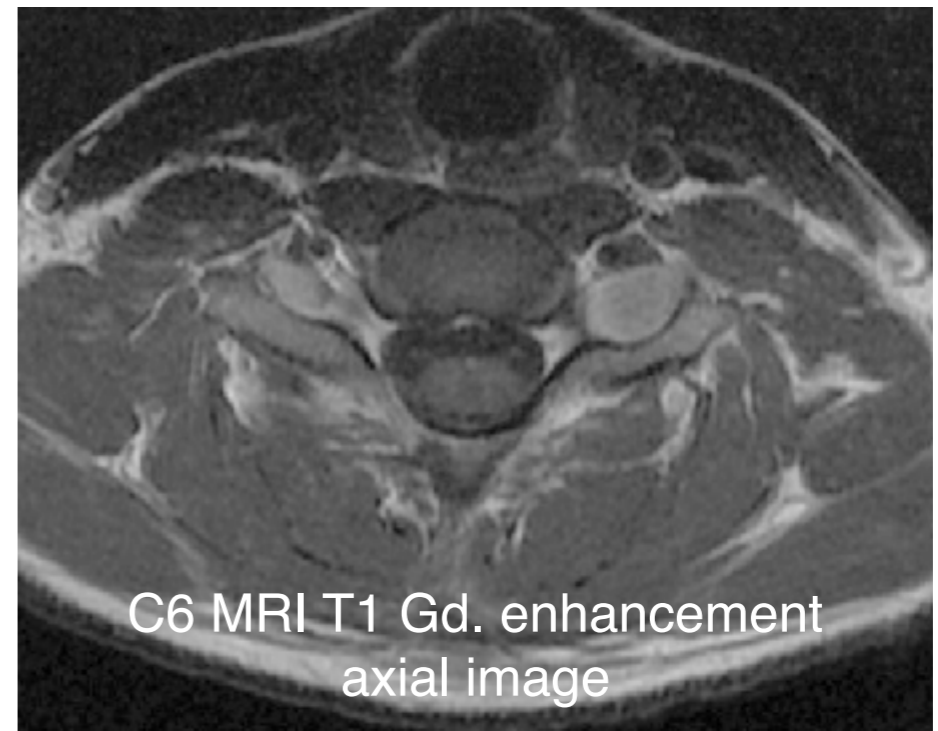
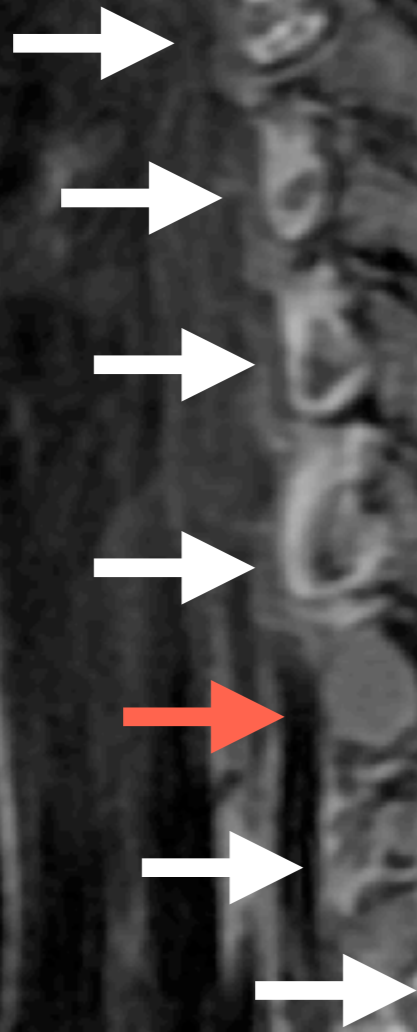


case 3

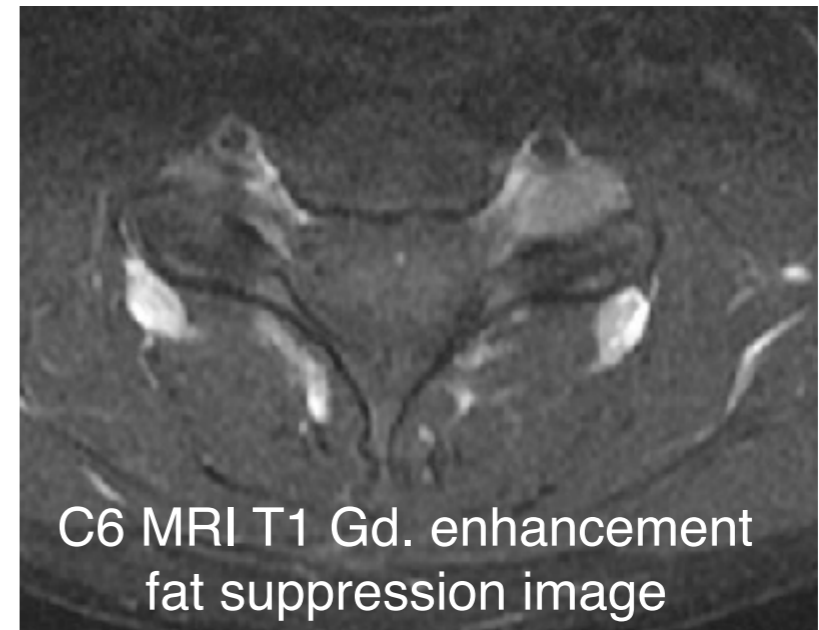
- 25 yo female elementary school teacher
- tingling sensation at Lt C7 area since last 5 years
- slowly exaggerated and became painful in the last few years
- finally diagnosed correctly by a neurologist after visiting tens of clinics

case 3

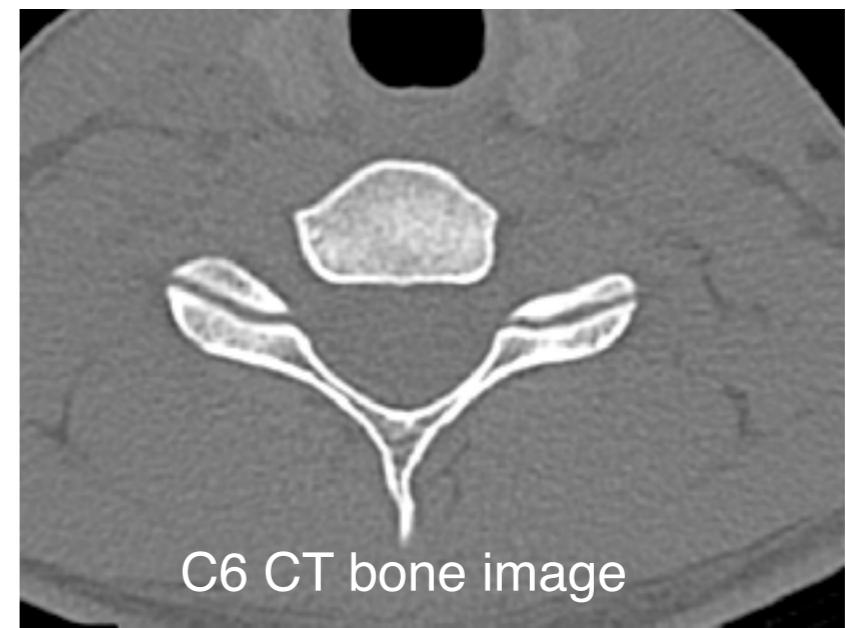lt neural foramen
MRI T1 with Gad. enhancement
para-sagittal image



C6 MRI T1 Gd. enhancement
axial image



C6 MRI T1 Gd. enhancement
fat suppression image



C6 CT bone image

case 4

- 58 yo male patient
- spastic paraparesis due to OYL at T2-4 recovered fully by T2-4 laminectomy without fusion
- spastic paraparesis recurred 8 years after

2000 CT

2000 MRI T2WI

2000 postoperative
CT myelo.

2008 CT

2008 MRI T2WI

